

Case Study:
*Mechanisms of Action for Balloon Dilation of the
Ostiomeatal Unit (OMU) in Patients with Chronic
Rhinosinusitis*

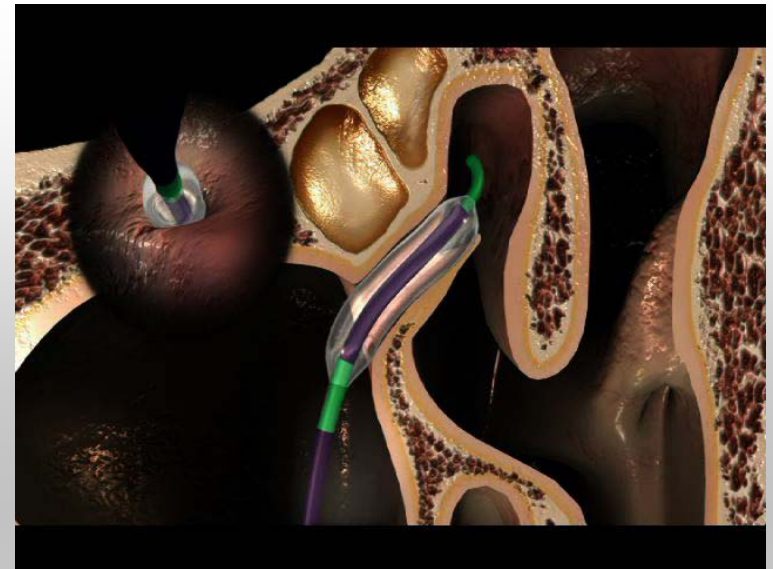
Jim Atkins, M.D.
Texas Sinus Center
San Antonio, TX

Financial Disclosures

- Paid Consultant: Entellus Medical, Inc.
(Scientific Advisory Board)
- Stock Shareholder: Entellus Medical, Inc.

Background

- FinESS released April 2008
- “How are you getting any benefit just dilating the ostia?”
- Ostial dilation is not the only component of the procedure
- Infundibular remodeling is also a large component



How Did We Know This?

- Intra and postoperative visualization of the medialized uncinata
- Intra-operative inspection of the infundibulum

Goal and Methodology

Goal

- To radiographically quantify the magnitude of the remodeling

Methodology

- Xoran MiniCAT™ CT; 0.4-mm slice spacing
- Visually and digitally aligned the pre/post op CT scans
- Three locations in the infundibulum were selected and compared pre and post op
- Cross-sectional area at each location was calculated using commercial software¹

¹ *Universal Desktop Ruler v3.2.3231 – Evaluation Version.*

Methodology

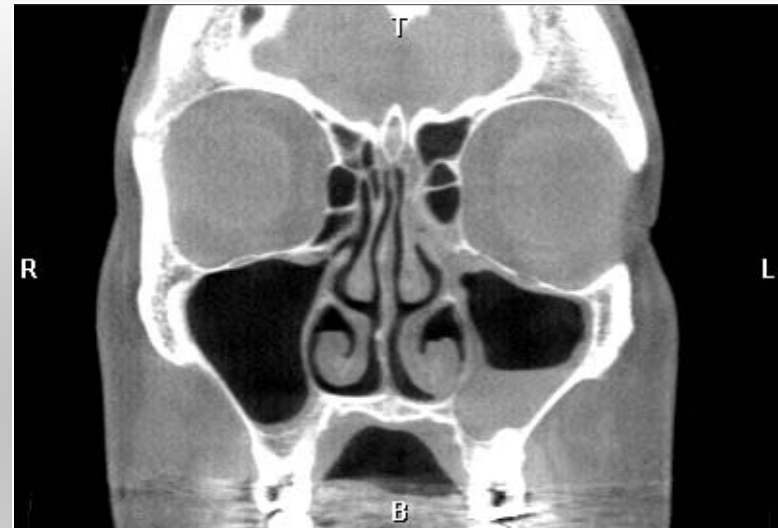
Case Study

- 53-Year Old Female
- Bilateral FinESS™ in Nov. 2007
- 5mm Balloon
- Local Anesthesia with IV Sedation

Follow-Up

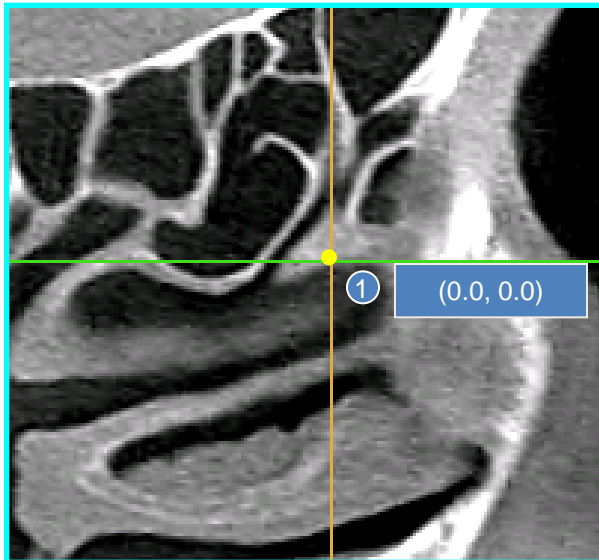
- CT Scan : 1 Month
- SNOT-20 QoI:
 - Baseline = 2.5
 - 6-Mo. = 1.5
 - 12-Mo. = 1.0

Baseline Evaluation CT Scan



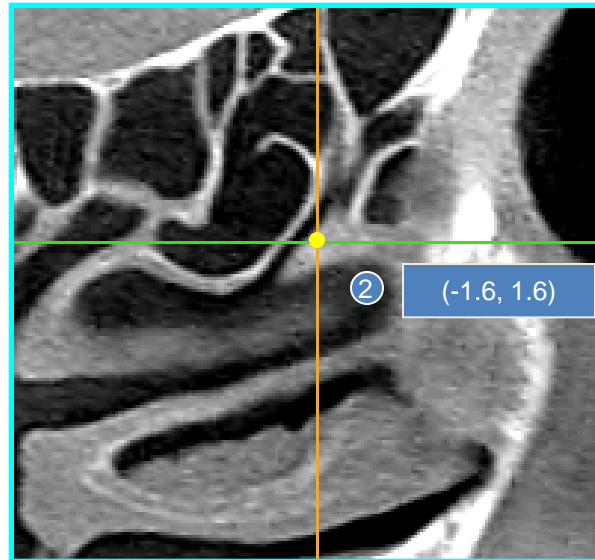
Methodology

Pre-Procedure CT: Left Maxillary Sinus & OMU



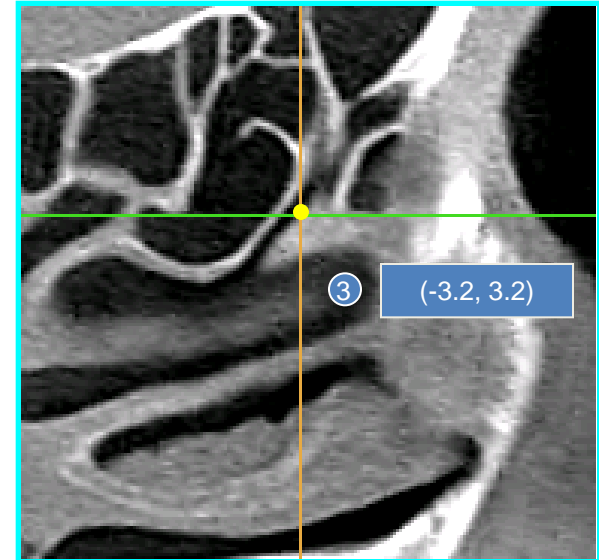
OMU Position #1

- Anterior, inferior slice (i.e. anterior maxillary ostium)
- Coronal and axial measurements



OMU Position #2

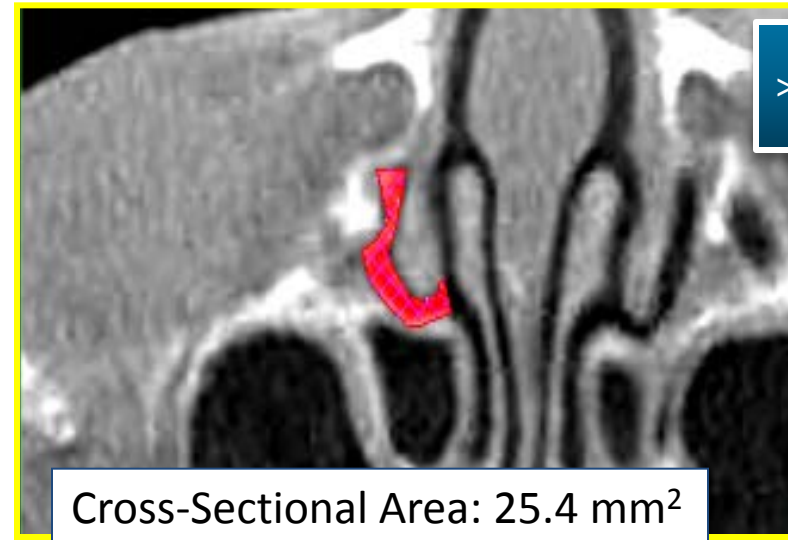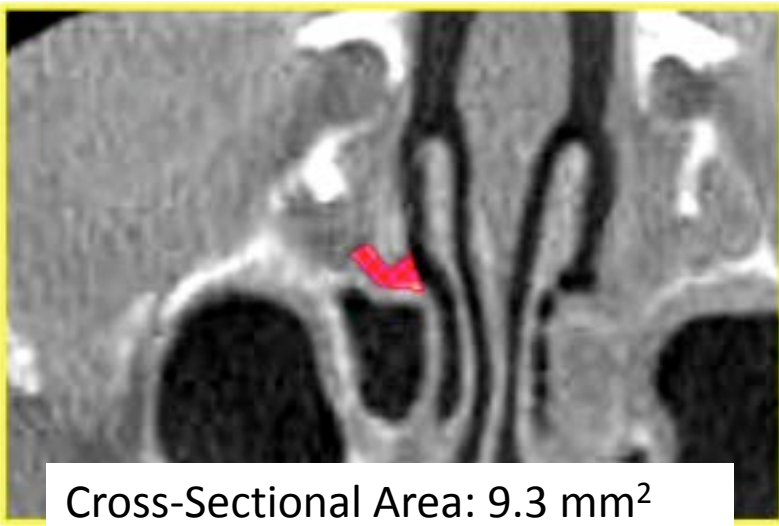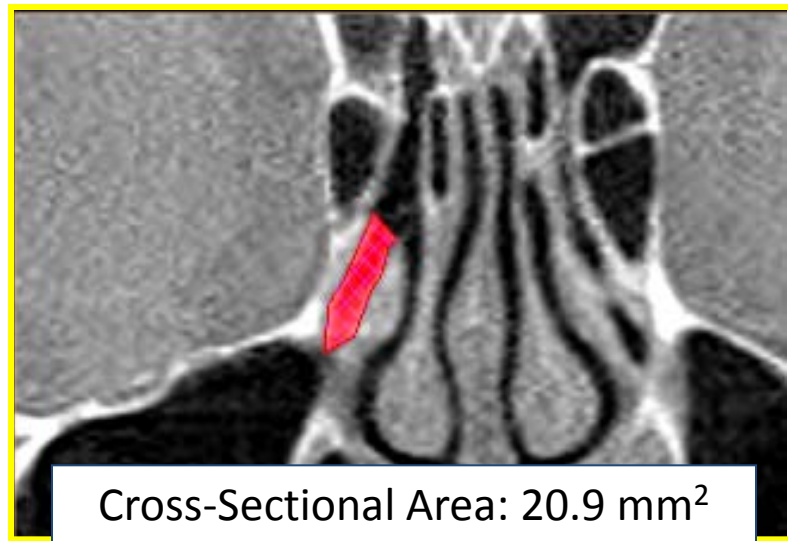
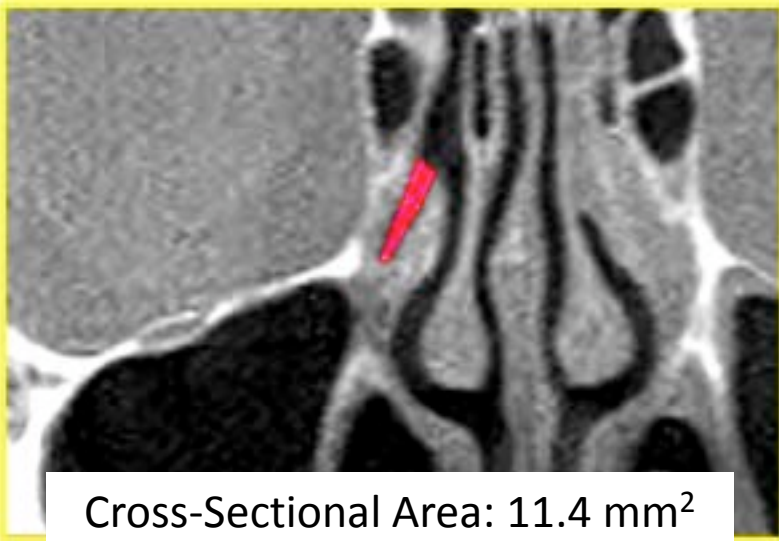- 4 slices (1.6 mm) Superior from #1
- 4 slices (1.6 mm) Posterior from #1
- Coronal and axial measurements



OMU Position #3

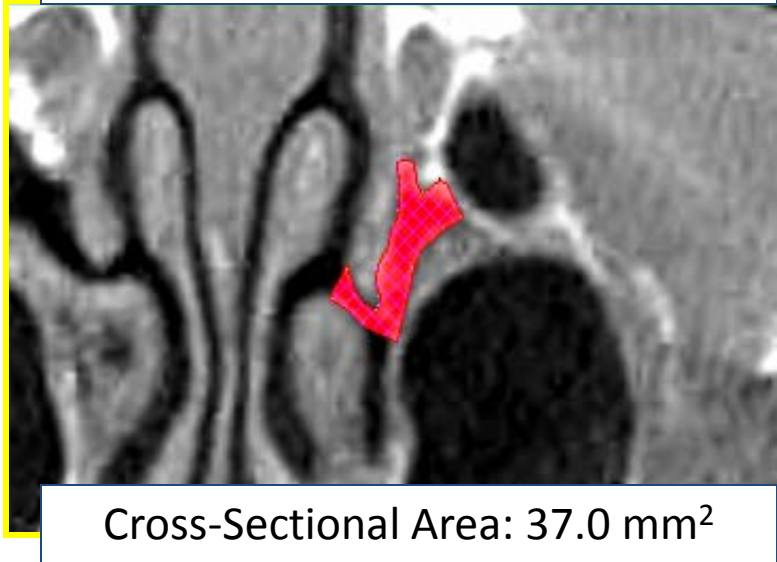
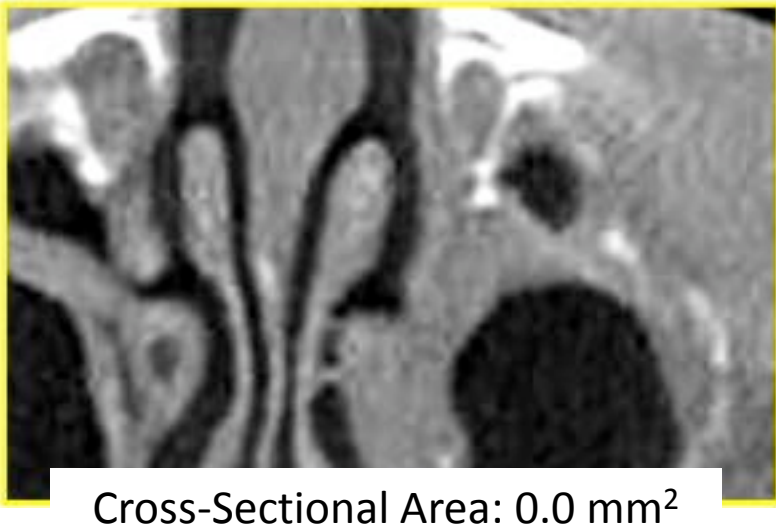
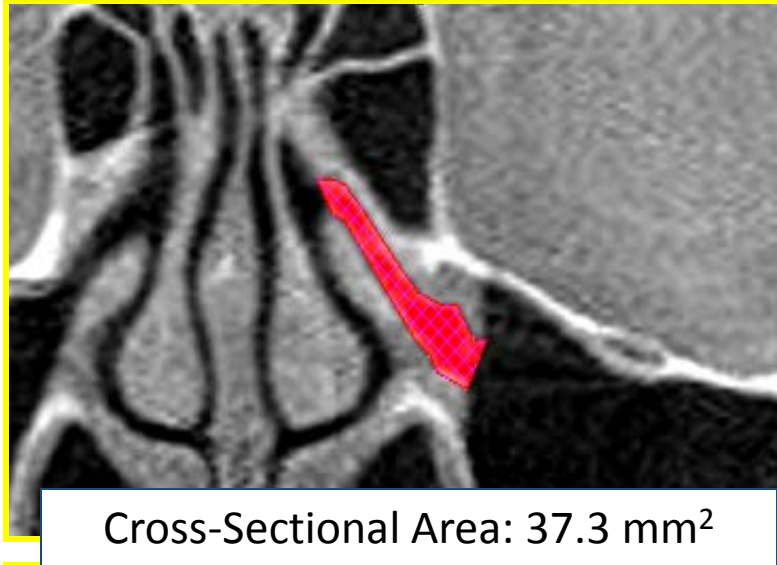
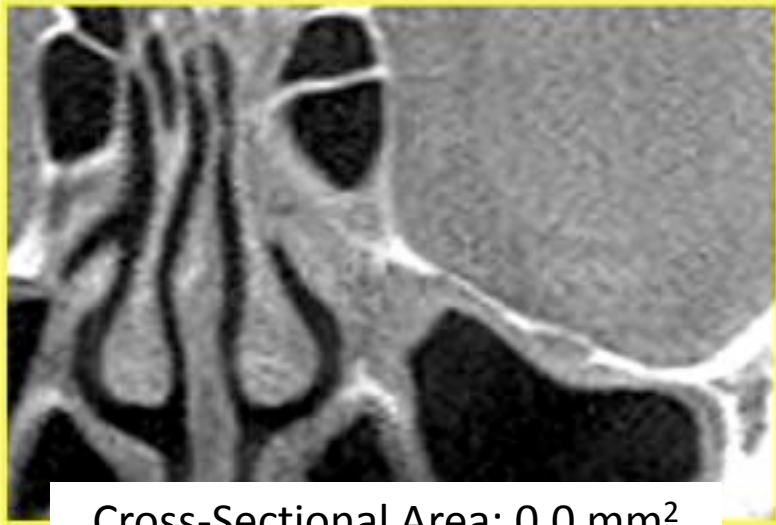- 8 slices (3.2 mm) Superior from #1
- 8 slices (3.2 mm) Posterior from #2
- Coronal and axial measurements

Right Side - OMU Position #1
Pre-Op Post Op



> 2X Increase

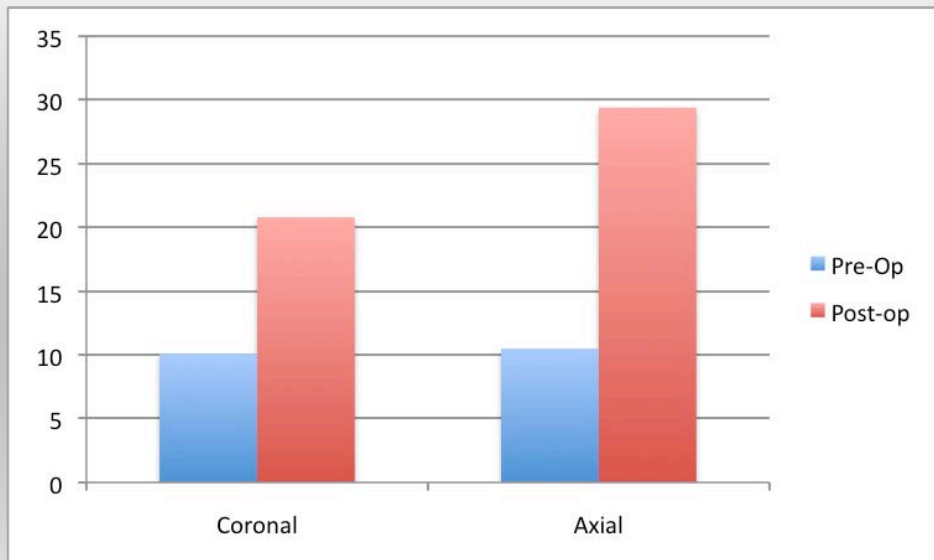
Left Side - OMU Position #1
Pre-Op Post Op



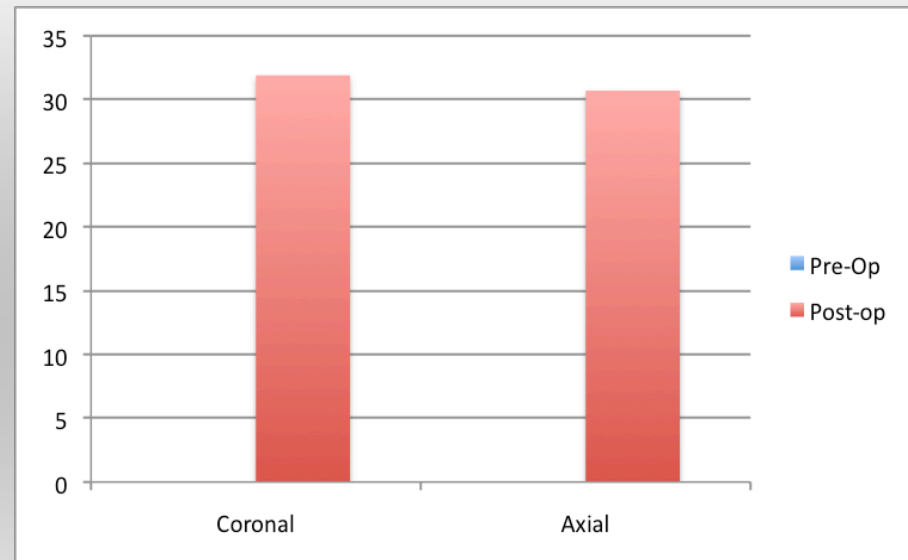


Average Results Over 3 Different Locations

Right (mm²)



Left (mm²)



Discussion

- Radiologic –

CT scanning has limitations for visualizing and quantifying changes to the infundibulum after balloon dilation

3-D Imaging may offer a alternative

- Clinically –

2D comparison suggests a 2 fold increase in cross-sectional area within the infundibulum after 5mm balloon dilation.

Conclusion

- Sustained expansion of the infundibulum is identifiable and measurable after FinESS.
- Optimal infundibular size post balloon dilation will need to be determined to assure proper mucociliary flow
- Sustained expansion combined with uncinata preservation are likely two of the key factors contributing to the success of this procedure.